Enfermedades de la medula espinal en el gato

Sergio Rodenas, DVM, MRCVS, Dip ECVN
Especialista europeo reconocido en Neurologia Veterinaria

Responsable de Neurologia y Neurocirugia
Hospital Veterinario de Blue care
Facebook Sergio Rodenas Neurologia Neurocirugia veterinaria

Principales Objetivos

- Examen físico
- Examen neurológico completo
- Determinar si el problema es neurológico
- Localizacion neuro-anatómica
- Establecer un diagnostico diferencial
- Exámenes complementarios, tratamiento y pronostico

Examen neurológico: Objetivos

Identificar/confirmar la presencia de un problema neurológico

2. **Localizar la lesión dentro del sistema nervioso**

Otros

- Evaluar la gravedad y extensión de la lesión
- Pronóstico

Sistema Nervioso

Sistema nervioso central (SNC)

- Encéfalo
- **Médula espinal**



Sistema nervioso periférico (SNP)

Localización de la lesión

NMS: Neurona motora superior *(UMN)*

NMI: Neurona motora inferior *(LMN)*

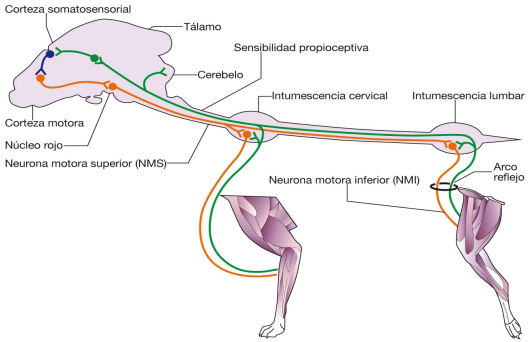

Función motora voluntaria

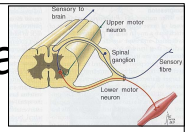

Controla actividad muscular (*encéfalo* a los *músculos*)

Contracción muscular: actividad extremidades

Déficit: ***PARESIA*** (debilidad)

Requiere 2 neuronas:

NMS

NMI

Función motora voluntaria

NMS

- ***Origen***: Encéfalo
- ***Destino:*** Médula espinal

  NMS ordena a NMI qué hacer (inhibición)

NMI

- ***Origen:*** Médula espinal
- ***Destino:*** SNP hasta músculo

  Responsible actividad refleja (e.g. reflejo patelar)

Función motora: Paresia/parálisis

Déficit función motora: Lesión NMS o NMI

- **PARESIA:** Déficit parcial

Ambulatoria o no ambulatoria

- **PARÁLISIS (-plegia)):** Ausencia completa

Monoparesia / Monoplegia
Paraparesia / Paraplegia
Tetraparesia / Tetraplegia
Hemiparesia / Hemiplegia

Médula espinal: Anatomía

Clasificación funcional: (segmentos)

C1-C5

C6-T2

T3-L3

L4-S3

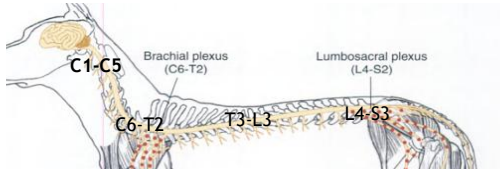

Localizacion en médula espinal

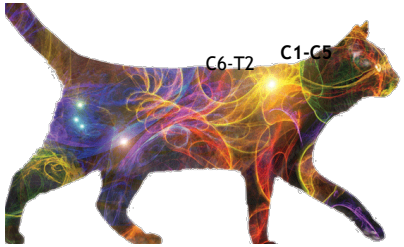

- **C6-T2 (NMI Ex ant/ NMS Ex post**
  - Tetraparesis/plegia
  - Hemiparesia/plegia/Monoparesia/plegia (lateralizado)
  - Déficits reacciones posturales 4 extremidades
  - Ataxia en las 4 extremidades
  - Reflejos: normales/aumentados Ex posteriores
  - Reflejos: disminuidos/ausentes Ex anteriores

Localizacion en médula espinal

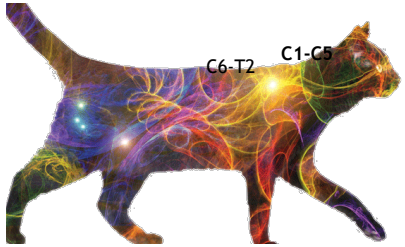

- **C1-C5 (NMS 4 extremidades)**
  - Paresia (tetraparesis/plegia)
  - Hemiparesia/plegia (lateralizado)
  - Déficits reacciones posturales 4 extremidades
  - Ataxia en las 4 extremidades
  - Reflejos: normales/aumentados

Localizacion en médula espinal

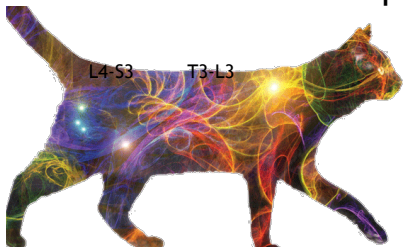

- **T3-L3(NMS Ext posteriores)**
  - Paraparesia / paraplegia (monoparesia/ plegia)
  - Ext Anteriores : Normales
  - E posteriores:
    - Déficits reacciones posturales
    - Ataxia
    - Reflejos normales/aumentados

Localizacion en médula espinal

- **L4-S3 (NMI Ext Posteriores)**
  - Paraparesia / paraplegia (monoparesia/plegia)
  - Incontinencia urinaria (NMI)
  - Ext anteriores: Normales
  - Ext Posteriores:
    - Déficits reacciones posturales
    - Ataxia leve a moderada (mas paresia que ataxia)
    - Reflejos disminuidos/ausentes

J Vet Intern Med 2004;18:851–858

Prevalence of Diseases of the Spinal Cord of Cats

Katia Marioni-Henry, Charles H. Vite, Alisa L. Newton, and Thomas J. Van Winkle

A retrospective review of records of 205 cats with histologically confirmed disease of the spinal cord was performed to identify the prevalence of disease in this nonrandomly selected population of cats. Clinical records were reviewed, and age, duration of neurologic illness, and clinical and histopathologic findings in cats with spinal cord disease were abstracted. Disease processes were classified into 7 categories and 23 groups. The most common diseases affecting the spinal cord of cats were feline infectious peritonitis (FIP), lymphosarcoma (LSA), and neoplasia of the vertebral column secondarily affecting the spinal cord. Information on age, onset and duration of clinical signs, and lesion localization at the postmortem examination in cats belonging to the 7 categories of disease were analyzed to create a practical list of differential diagnoses. Cats were also subcategorized into 3 groups based on their age at death. FIP was the most common disease of cats younger than 2 years of age. LSA and vertebral column neoplasia were the most common diseases affecting cats between 2 and 8 years of age. Vertebral column neoplasia was the most common disease affecting cats older than 8 years of age. Results of this histopathologic study showed that FIP and LSA were the most common disease processes affecting the spinal cord of cats. However, at least 21 other groups of diseases and their relative prevalence were identified.

Inflamatorio – 32%
Neoplasia – 27%
Trauma – 14%
Congénita – 11%
Vascular – 9%
Degenerativo – 6%

Table 1. Categories and groups of spinal cord disease in 205 cats.

Categories of Diseases[a]	No. Cats[b]	Disease Groups[c]	No. Cats[b]
Inflammatory or infectious	64 (32)	Feline infectious peritonitis	33 (16)
		Bacterial or suspected bacterial myelitis	10 (5)
		Cryptococosis	6 (3)
		Unknown infectious or inflammatory	5 (2)
		Toxoplasmosis	4 (2)
		Eosinophilic meningomyelitis	3 (1)
		Idiopathic poliomyelitis	3 (1)
Neoplastic	56 (27)	Lymphosarcoma	20 (10)
		Vertebral column neoplasia	17 (8)
		Meningeal neoplasia	7 (3)
		Extradural nonvertebral column neoplasia	6 (3)
		Intramedullary neoplasia	6 (3)
Traumatic	28 (14)	Secondary to vertebral column injury	15 (7)
		Intervertebral disc disease	8 (4)
		Secondary to a penetrating wound	5 (2)
Congenital or inherited	22 (11)	Storage disease affecting spinal cord	14 (7)
		Mucopolysaccharidosis VI	5 (2)
		Syringohydromyelia	3 (1)
Vascular	19 (9)	Ischemia or infarct	15 (7)
		Focal malacia	4 (2)
Degenerative	13 (6)	Neuroaxonal dystrophy	7 (3)
		Other degenerative diseases	6 (3)
Metabolic	3 (1)	Metabolic	3 (1)

Clinical and magnetic resonance imaging findings in 92 cats with clinical signs of spinal cord disease

Rita Gonçalves DVM, MRCVS[1*], **Simon R Platt** BVM&S, Dip ACVIM, Dip ECVN, MRCVS[2], **Francisco J Llabrés-Díaz** DVM, DVR, Dip ECVDI, MRCVS[3], **Katherine H Rogers** MA[4], **Alberta de Stefani** DVM, Dip ECVN, MRCVS[5], **Lara A Matiasek** DVM, Dip ECVN, MRCVS[5], **Vicki J Adams** DVM, BSc, MSc, PhD[4]

[1]*Institute of Comparative Medicine, Division of Companion Animal Sciences, Faculty of Veterinary Medicine, University of Glasgow, Glasgow, UK*
[2]*Department of Small Animal Medicine, College of Veterinary Medicine, University of Georgia, Athens, USA*
[3]*Davies Veterinary Specialists, Manor Farm Business Park, Higham Gobion, UK*
[4]*Animal Health Trust, Centre for*

Medical records of 92 cats presented with clinical signs of spinal cord disease, which had undergone magnetic resonance imaging (MRI), were reviewed. The cats were grouped into seven categories based upon the diagnosis suggested by results of MRI, cerebrospinal fluid analysis and other diagnostic procedures: neoplastic ($n = 25$), inflammatory or infectious ($n = 13$), traumatic ($n = 8$), vascular ($n = 6$), degenerative ($n = 5$), anomalous ($n = 3$) and those with an unremarkable MRI ($n = 32$). There were two independent predictors of abnormal MRI findings: severity of clinical signs and presence of spinal pain. Abnormal MRI findings and speed of onset of disease were significantly associated with survival. For the 32 cats with unremarkable MRI findings, only nine died due to spinal disease and, therefore, the median survival time (MST) was not reached (lower 95% confidence interval (CI) = 970 days). For the 60 cats with abnormal MRI findings, 37 died due to their disease and the MST was 138 days (95% CI:

Inflamatorio – 14%
Neoplasia – 27%
Trauma – 9%
Congénita – 3%
Vascular – 6.5%
Degenerativo – 5,4%

Examenes complementarios

Exploración general
Ganglios, temperatura, mucosas.

- Oftalmológico
  Uveitis (toxoplasma,PIF) Coriorretinitis (PIF, Toxoplasma)

Cardio-respiratorio
Rinorrea, metástasis, síncopes

Gastrointestinal
Enf hepáticas, pancreáticas (insulinoma)

- Urinario, reproductivo, tegumentario

Uveitis y neuritis optica Toxoplasma

Uveitis PIF

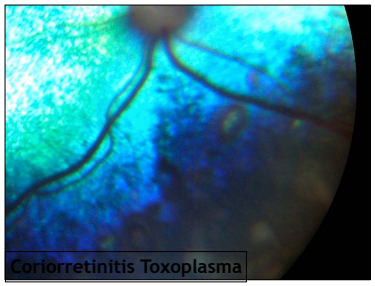
Coriorretinitis Toxoplasma

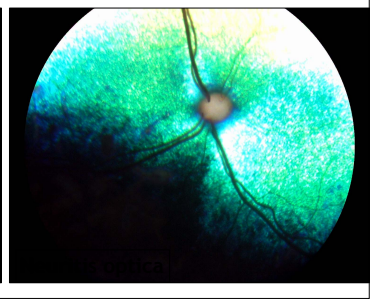

Examenes complementarios

- Analitica completa (hemograma y bioquimica), proteinograma
- FeLV /FIV
- Ecografia abdominal (liquido libre, renomegalia, etc). PIFs Linfomas
- Radiografias de Torax (neoplasia, neumonia, efusion pleural
- Enfermedades infecciosas (Toxoplasma, micoplasma, PIF, etc)

Examenes complementarios

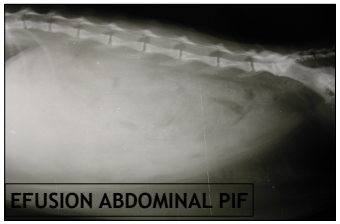
EFUSION ABDOMINAL PIF

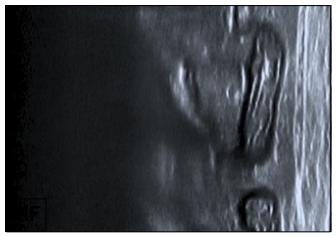

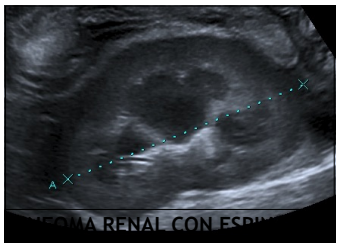
NFOMA RENAL CON ESPI

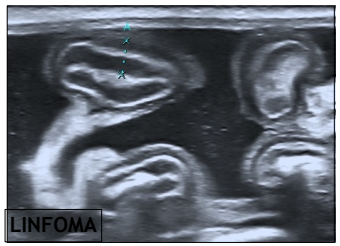
LINFOMA

DIAGNOSTICO DIFERENCIAL GATOS CON PARA/TETRAPARESIA AGUDA

- TRAUMATISMO (Fractura/luxacion, contusion medular, etc)
- EMBOLISMO FIBROCARTILAGINOSO (Prevalencia en gatos mayores)
- HERNIA DISCAL HANSEN I O TRAUMATICA (disco no degenerado)
- NEOPLASIA (Linfoma, osteosarcoma con fractura patologica, etc)
- MENINGOMIELITIS (PIF, toxoplasma, etc)
- TROMBOEMBOLISMO AORTICO (neuromiopatia)

DIAGNOSTICO DIFERENCIAL GATOS CON PARA/TETRAPARESIA CRONICA

- NEOPLASIA (Linfoma, osteosarcoma con fractura patologica, etc)
- MENINGOMIELITIS (PIF, toxoplasma, etc)
- HERNIA DISCAL HANSEN II
- ANOMALIAS CONGENITAS (Quiste aracnoideo, meningocele, etc)
- NEUROMUSCULAR (NO ATAXIA)

MIELOPATIA ISQUEMICA (EFC)

MIELOPATIAS ISQUEMICAS (EMBOLISMO FIBROCARTILAGINOSO)

Occlusion de la vascularizacion medular por un material fibrocartilaginoso identico al nucleo pulposo del disco intervertebral.

- FUENTES DEL FIBROCARTILAGO

Núcleo pulposo

Placa crecimiento en vertebra

Metaplasia del endotelio vascular

MIELOPATIA ISQUEMICA (EFC)

FISIOPATOLOGIA COMO ENTRA EL MATERIAL EN LA VASCULARIZACION?? 5 HIPOTESIS

-1) PENETRACION DIRECTA DE FRAGMENTOS DE NUCLEO PULPOSO

Arterias espinales
Venas espinales mediante fistulas arteriovenosa

-2) NEOVASCULARIZACION CRONICA INFLAMATORIA DE UN DISCO DEGENERADO

Aumento de presion discal > presion arterial, penetracion fibrocartilago en neo-vasos de ahí a vasos espinales

-3) VASO EMBRIONARIOS REMANENTES(mismo mecanismo que el anterior

-4 HERNIACION MECANICA DEL NP EN MEDULA OSEA VERTEBRAL

Vasos o canales sinusoides, entrada retrograda vena basivertebral, vasos espinales

Tetraparesia o tetraplejia aguda

Neuro-anatomía vascular

Riego arterial médula espinal

Ligeras variaciones entre especies: parecido en mamíferos

Arterias superficiales
- Arterias dorsolaterales o tronco dorsolateral
- Arteria espinal ventral
- Arterias de anastomosis
- Arterias espinales
  - Arteria radicular dorsal
  - Arteria radicular ventral

Arterias profundas
- Arterias verticales
- Arterias radiales

Neuro-anatomía vascular

Riego arterial médula espinal

Arterias lumbares (aorta)
Arterias intercostales
Arterias vertebrales
} **Arterias espinales**

Arteria radicular ventral → Arteria ventral espinal

Arteria radicular dorsal → Arterias dorsolaterales

Arterias de anastomosis

Conectan arterias dorsolaterales y arteria ventral espinal

Neuro-anatomía vascular

Arterias profundas espinales

Arterias verticales

Salen de la arteria ventral espinal
fisura ventral
hacia centro médula espinal

Mayoría sustancia gris

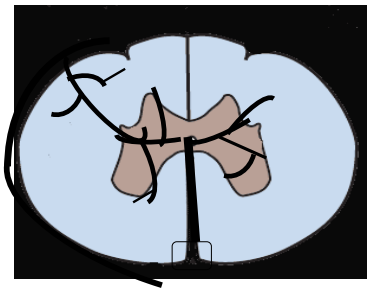

Arterias radiales

Salen de otras arterias superficiales.
Sustancia blanca y superficie sustancia gris

Neuro-anatomía vascular

Zonas vasculares

Zona interna vascular

Art verticales

Zona media vascular

Art verticales
Art radiales

Zona externa vascular

Art radiales

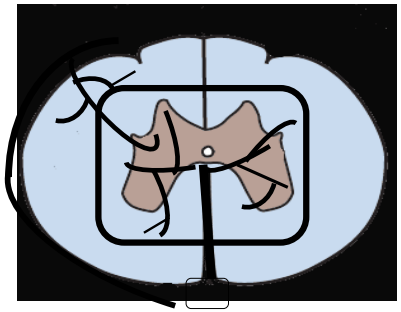

Neuro-anatomía vascular

Accidentes vasculares espinales

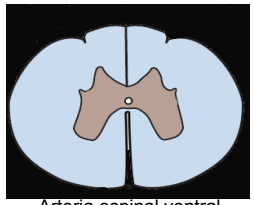

Arteria espinal ventral

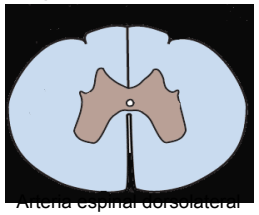

Arteria espinal dorsolateral

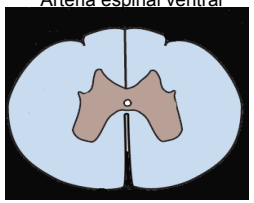

Arterias vaso-corona (radiales)

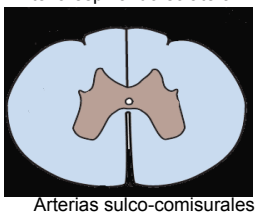

Arterias sulco-comisurales

Cervós-Navarro & Schneider, 1980

FEC EN GATOS

MIELOPATIA ISQUEMICA (EFC)
GATOS

Clinical outcome in 19 cats with clinical and magnetic resonance imaging diagnosis of ischaemic myelopathy (2000–2011)

Journal of Feline Medicine and Surgery
15(2) 132–141
© ISFM and AAFP 2012
Reprints and permission:
sagepub.co.uk/journalsPermissions.nav
DOI: 10.1177/1098612X12463927
jfms.com
SAGE

58%)

Anita Theobald[1], Holger A Volk[2], Ruth Dennis[1], Davide Berlato[1] and Luisa De Risio[1]

Abstract

Previous publications on ischaemic myelopathy in cats are limited to single case reports and small case series. The overall prognosis appears poor, with 42% of cats being euthanased. In this study the clinical outcome of 19 cats with a presumptive diagnosis of ischaemic myelopathy [based on clinical and magnetic resonance imaging (MRI) findings] was evaluated retrospectively. The degree of neurological dysfunction at the time of presentation was similar to previously reported cases, ranging from ambulatory paresis to plegia with intact nociception. The most common lesion localisations (based on MRI) were to the C1–C5 (30%) and C6–T2 (30%) spinal cord segments, with the T3–L3 and L4–S1 spinal cord segments accounting for 25% and 15%, respectively. Potential inciting or predisposing causes for development of spinal infarction were identified in 12 cats, including physical exertion, trauma, general anaesthesia, renal disease, hyperthyroidism, hypertension and hypertrophic cardiomyopathy. The median time to recovery of ambulation was 3.5 days (3–19 days). Four cats (21%) were euthanased within 2 months of diagnosis. The remaining 15 (79%) cats had a favourable outcome. Follow-up ranged from 6 months to 10 years and 4 months, with a median of 3 years and 1 month. Even when plegia was present at the time of presentation, all surviving cats with long-term, owner-derived follow-up were reported to return to a normal quality of life, suggesting that the long-term prognosis for recovery from presumed ischaemic myelopathy is favourable in the majority of cats.

IAS)

MIELOPATIA ISQUEMICA EN GATOS

DIAGNOSTICO

RMN

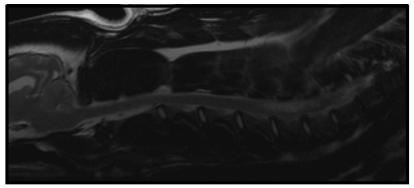

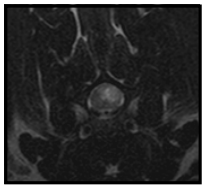

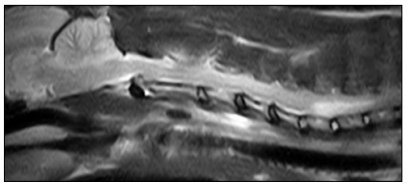

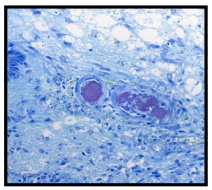

MIELOPATIA ISQUEMICA
(EFC)

Feline ischaemic myelopathy with a predilection for the cranial cervical spinal cord in older cats

1–9
© ISFM and AAFP 2014
Reprints and permissions:
sagepub.co.uk/journalsPermissions.nav
DOI: 10.1177/1098612X14522050
jfms.com
SAGE

Katherine M Simpson[1], Luisa De Risio[2], Anita Theobald[2], Laurent Garosi[1] and Mark Lowrie[1]

Abstract

All previous studies on feline ischaemic myelopathy (IM) have reported an acute onset of a single event with no recurrence of clinical signs. This study aimed to evaluate clinical and long-term follow-up data in cats presumptively diagnosed with cervical IM in the territory of the ventral spinal artery (VSA). Eight cats (four females and four males) were included with a mean age of 14 years and 2 months. Neurological status at the time of presentation ranged from ambulatory tetraparesis to tetraplegia with nociception present. Six cats had marked cervical ventroflexion. All eight cats were diagnosed with one or more concurrent medical conditions, including chronic kidney disease (n = 2), hypertrophic cardiomyopathy (n = 2) and hypertension (n = 6). Median time to ambulation was 5.7 days (range 2–14 days). Long-term follow-up ranged from 7 months to 3 years and 3 months (median 1 year and 2 months). Five cats had no reported recurrence of clinical signs and 3/8 had a chronic relapsing disease course. One cat had an acute recurrence of clinical signs 4 months after the first event and was euthanased. Two cats had acute onsets of suspected intracranial infarctions, one of which had further suspected intracranial infarcts every 3 months and was euthanased after one of these. This study highlights the importance of performing ancillary diagnostic tests in older cats presenting with IM, particularly when VSA embolisation is suspected.

MIELOPATIA ISQUEMICA (EFC)

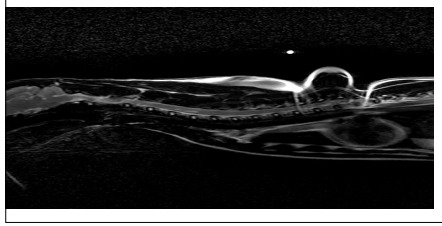

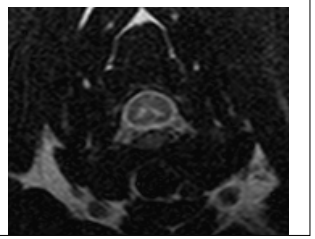

MIELOPATIA ISQUEMICA (EFC)

Feline ischemic myelopathy and encephalopathy secondary to hyaline arteriopathy in five cats

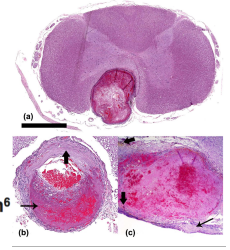

Helena Rylander[1], Salih Eminaga[2], Viktor Palus[2], Howard Steinberg[3], Abby Caine[2], Brian A Summers[4], Joshua Gehrke[5], Chad West[5], Philip R Fox[5], Taryn Donovan[6] and Giunio Bruto Cherubini[2]

Abstract

Five cats presented with acute-onset neurological signs. Magnetic resonance imaging in four cats showed a T2-weighted hyperintense spinal cord lesion that was mildly contrast-enhancing in three cats. Owing to inflammatory cerebrospinal fluid changes three cats were treated with immunosuppression. One cat was treated with antibiotics. All cats improved initially, but were eventually euthanased owing to the recurrence of neurological signs. Histopathology in all cats showed hyaline degeneration of the ventral spinal artery, basilar artery or associated branches with aneurysmal dilation, thrombosis and ischemic degeneration and necrosis of the spinal cord and brain. Two cats also had similar vascular changes in meningeal vessels. Vascular hyaline degeneration resulting in vascular aneurysmal dilation and thrombosis should be a differential diagnosis in cats presenting with acute central nervous system signs.

ENFERMEDADES INFLAMATORIAS

- ENFERMEDADES INFECCIOSAS

ENFERMEDADES VIRICAS → **PIF**

PROTOZOARIAS → **Toxoplasma**

BACTERIANA → **Abscesos Mordeduras**

FUNGICAS/PARASITARIAS → **Cuterebra Criptococos**

- ENCEPHALITIS ORIGEN DESCONOCIDO (INMUNOMEDIADA?)

MENINGOMIELITIS

AGENTES ETIOLOGICOS DESCRITOS EN LITERATURA

- **PERITONITIS INFECCIOSA FELINA**
  FIV, FeLV, Parvovirus felino
  Virus de la rabia
  Virus pseudorrabia (herpesvirus porcion)
  Virus de la encefalomielocarditis
  Virus del Borna
  West Nile virus
  Bacterianas
  Ricketsias
  Parasitarias (nematodos, cuterebra..)
  Protozoos (TOXOPLASMA)

MENINGOMIELITIS

PERITONITIS INFECCIOSA FELINA

Incidencia; 44-51% gatos con inflamacion del SNC

Mayor incidencia en gatos de 6 meses a 2 años

Signos focales (medula espinal, encefalo) o multifocales (mas frecuente)

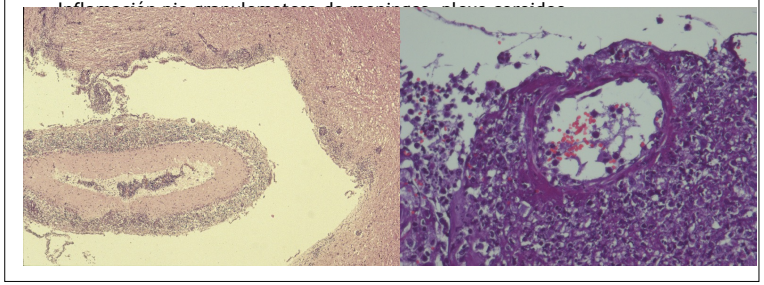

- Peritonitis infeciosa felina (PIF)

(coronavirus)

- Mutacion del coronavirus enterico (via mas frecuente a traves de heces)

- Generalmente gatos jóvenes < 3 años (Hasta 15 años descritos)

-1) Forma humeda (poliserositis), efusiones pleural, abdominal
< 9% signos neurológicos

-2) Forma seca (piogranulomatosa)
1/3 gatos signos neurológicos

- 45-50% inflamaciones SNC gatos

-15-20% de todos los casos neurológicos felinos

- Peritonitis infeciosa felina (PIF)

Forma sistemica Puede ir acompañada de las otras formas

anorexia, pérdida peso, diarreas.

Forma ocular

UVEITIS, coriorretinitis, otros signos.

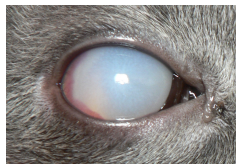

Forma neurológica (multifocal/focal)

Alteración estado mental
Cerebelo/vestibulares
Signos mielopatía (ataxia, paresia)
Convulsiones

- Peritonitis infeciosa felina (PIF)

Diagnóstico TESTS INDIRECTOS

CBC (anemia no regenerativa, leucocitosis)

Bioquímica
Hiperglobulinemia (70% en forma seca)
Gammopatia policlonal, alteraciones renal, hepática

Radiografias torácicas/abdomen (efusiones)

Analisis de las efusiones (exudado inflamatorio)

Citologia del humor acuoso en gatos con uveitis

Deteccion de Ac de Coronavirus (efusiones, sangre, LCR, etc)

Test de Rivalta (exudado en acido acetico), no especifico de PIF

RT-PCR coronavirus en heces

- Peritonitis infeciosa felina (PIF)

Diagnóstico TESTS INDIRECTOS

IMAGEN AVANZADA TAC O RMN

TAC

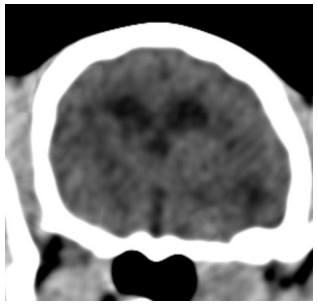

Pre-contraste

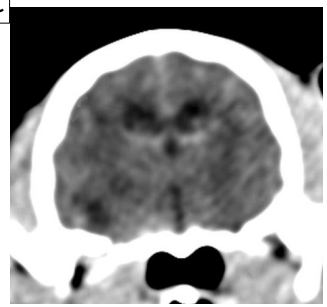

Post-contraste

- Peritonitis infeciosa felina (PIF)

Diagnóstico **RMN** ***Cortesia de A Negrin. Dick White Referrals***

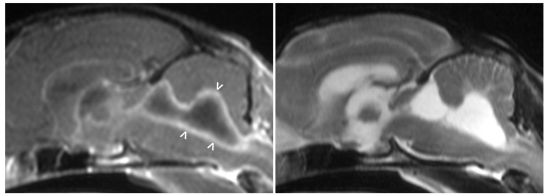

T1 + gadolinium **T2**

LCR

Severa pleocitosis neutrofílica generalmente

Casos descritos con LCR normal

SEROLOGIAS Ac Coronavirus LCR ayuda al diagnostico

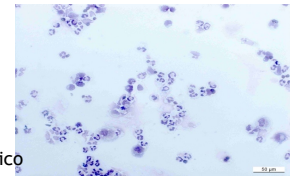

Diagnostic utility of cerebrospinal fluid immunocytochemistry for diagnosis of feline infectious peritonitis manifesting in the central nervous system

Journal of Feline Medicine and Surgery
1–11
© The Author(s) 2016
Reprints and permissions:
sagepub.co.uk/journalsPermissions.nav
DOI: 10.1177/1098612X16640839
jfms.com
This paper was handled and processed by the European Editorial Office (ISFM) for publication in JFMS
SAGE

Stefanie Gruendl[1], Kaspar Matiasek[2], Lara Matiasek[1], Andrea Fischer[1], Sandra Felten[1], Konrad Jurina[3] and Katrin Hartmann[1]

Abstract

Objectives The aim of the study was to evaluate whether an ante-mortem diagnosis of central nervous system (CNS) feline infectious peritonitis (FIP) is possible via immunocytochemical staining (ICC) of feline coronavirus antigen (FCoV) within macrophages of cerebrospinal fluid (CSF).

Methods Prospectively, CSF samples of 41 cats were investigated, including cats with histopathologically confirmed FIP and neurological signs (n = 10), cats with confirmed FIP without CNS involvement (n = 11), cats with neurological signs but another confirmed CNS disease (n = 17), and cats without neurological signs and a disease other than FIP (n = 3). ICC staining of CSF macrophages was performed in all cats. Sensitivity, specificity, positive (PPV) and negative predictive values (NPV) of CSF ICC were calculated.

Results Of 10 samples from cats with CNS FIP, eight had detectable CSF macrophages, seven of which were positive for FCoV. Ten of 11 samples from cats with confirmed FIP without neurological signs had macrophages in the CSF, with all 10 being ICC-positive. In cats with other CNS disorders, 11/17 had macrophages, two of which stained positively. In cats with diseases other than FIP and without neurological disorders, 2/3 revealed macrophages, with one cat showing positive ICC staining. Diagnosis of FIP via CSF ICC had a sensitivity of 85.0% and a specificity of 83.3%. PPV and NPV were 85.0% and 83.3%.

Conclusions and relevance CSF ICC is a highly sensitive test for ante-mortem diagnosis of FIP manifesting in the CNS. However, CNS ICC specificity is too low to confirm FIP and the method should only be applied in conjunction with other features such as CSF cytology. CNS ICC could be helpful to discover pre-neurological stages of CNS FIP.

- Peritonitis infeciosa felina (PIF)

DIAGNOSTICO POST MORTEM en SNC

Exudado e infiltracion piogranulomatosa en plexos coroideos, meninges y parenquima

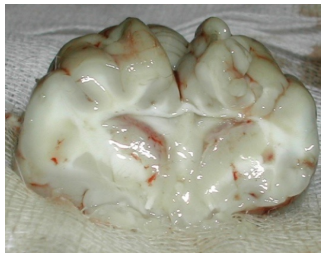

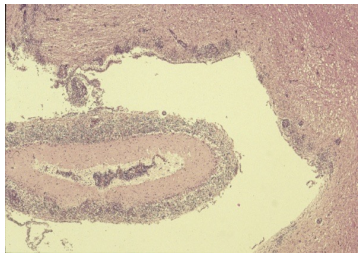

MENINGOMIELITIS GATOS

MENINGOENCEFALOMIELITIS DE ORIGEN DESCONOCIDO (VIRICAS?)

Relativamente frecuentes

En la mayoria de casos pleocitosis leve a moderadad

Ausencia de lesiones en RMN en la mayoria de casos

- Diagnostico en base a RMN, LCR (pleocitosis mixta o mononuclear) y serologias o PCRs de enfermedades infecciosas negativas

Tratamiento inmunosupresor (corticoesteroides) mas citarabina o ciclosporinas.

Pronostico variable (muchos casos responden bien)

Journal of Feline Medicine and Surgery
14(4) 250–256
© ISFM and AAFP 2012
Reprints and permission:
sagepub.co.uk/journalsPermissions.nav
DOI: 10.1177/1098612X11435460
jfms.com
SAGE

Slowly progressive lymphohistiocytic meningoencephalomyelitis in 21 adult cats presenting with peculiar neurological signs

Luisa De Risio[1], Richard Brown[2], Bryn Tennant[3], Andy Sparkes[4], Lara Matiasek[1,5], Alberta de Stefani[1], Herbert Weissenböck[6] and Kaspar Matiasek[1,7]

Abstract

Twenty-one cats presented with a history of slowly progressive neurological signs characterised by a stiff extended tail, behavioural changes, and spastic and ataxic gait. All cats had outdoor access and lived in the same geographical rural area in north-east Scotland. Histological findings were consistent with lymphohistiocytic meningoencephalomyelitis. Immunohistochemistry ruled out 15 pathogens and showed a significant expression of the interferon-inducible Mx protein, suggesting an as yet unidentified infective or environmental immunogenic trigger as the possible causative agent. The late age at onset (mean 9 years), the very slow progression of clinical signs (mean 11 months) and the peculiar clinical presentation (particularly the posture of the tail) have not been reported previously in cats with lymphohistiocytic meningoencephalomyelitis.

ROBOTIC CATS

Clinica lenta y progresiva, edad de aparicion gatos mayores, pronostico muy reservado

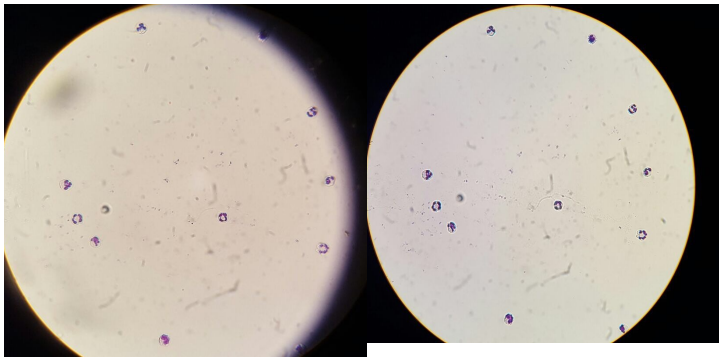

MENINGOENCEFALOMIELITIS ORIGEN DESCONOCIDO

INFECCIOSOS (ABSCESO)

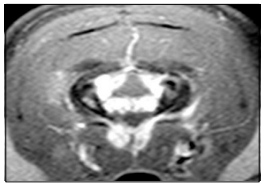

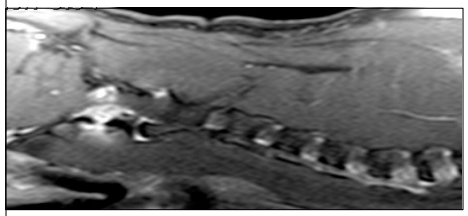

HERNIAS DISCALES DEGENERATIVAS GATOS

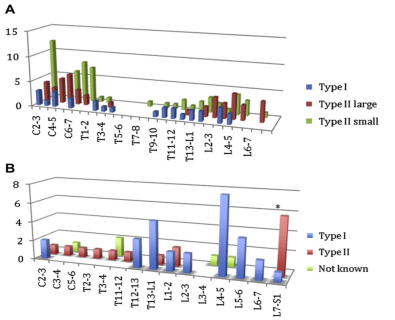

Fig. 5. (A) Prevalence of intervertebral disc protrusions in a population of 100 clinically unaffected cats (135 protrusions). (*Modified from* King AS, Smith RN. Disc protrusion in

- MENOS FRECUENTE QUE EN EL PERRO MAS FRECUENTES LAS PROTRUSIONES HANSEN I
- PRONOSTICO EN GENERAL FAVORABLE
- TRATAMIENTO DE ELECCION CIRUGIA

HERNIA DISCAL HANSEN I

HERNIA DISCAL HANSEN II

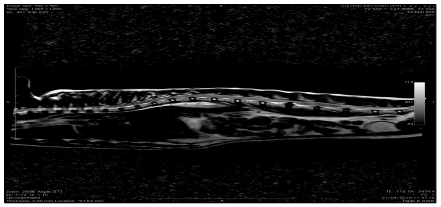

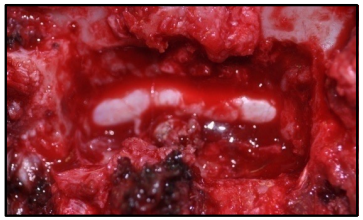

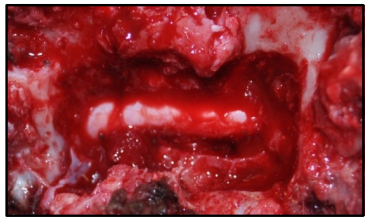

HERNIAS DISCALES TRAUMATICA DE DISCO NO DEGENERADO

Presumptive acute non-compressive nucleus pulposus extrusion in 11 cats: clinical features, diagnostic imaging findings, treatment and outcome

1–6
© The Author(s) 2015
Reprints and permissions:
sagepub.co.uk/journalsPermissions.nav
DOI: 10.1177/1098612X15605150
jfms.com
SAGE

Frances E Taylor-Brown and Steven De Decker

Abstract

Objectives The aim of the study was to describe the clinical features, diagnostic imaging findings, treatment and outcome in cats diagnosed with presumptive acute non-compressive nucleus pulposus extrusion.

Methods Medical records and imaging studies of cats diagnosed with presumptive acute non-compressive nucleus pulposus extrusion were retrospectively reviewed. Information on long-term outcome was acquired from patient records and from either owners or referring veterinary surgeons via a telephone questionnaire.

Results Eleven cats met the inclusion criteria. All cats had a peracute onset of clinical signs, with eight cats experiencing witnessed (n = 6) or suspected (n = 2) external trauma based on imaging findings. Neuroanatomical localisation included C1–C5 (n = 1), T3–L3 (n = 7) and L4–S3 (n = 3) spinal cord segments. Magnetic resonance imaging revealed acute non-compressive nucleus pulposus extrusions located at C3–C4 (n = 1), T12–T13 (n = 1), T13–L1 (n = 1), L1–L2 (n = 1), L3–L4 (n = 3), L4–L5 (n = 1) and L5–L6 intervertebral disc spaces (n = 3). Treatment included supportive care and 10 cats were discharged with a median hospitalisation time of 10 days (range 3–26 days). One cat was euthanased during hospitalisation owing to complications unrelated to neurological disease. All cats that presented non-ambulatory regained an ambulatory status with the median time to ambulation of 17 days (range 6–21 days). Overall, the outcome for cats diagnosed with acute non-compressive nucleus pulposus extrusion was successful, with almost 90% returning to ambulation with urinary and faecal continence.

Conclusions and relevance The majority of cats diagnosed with acute non-compressive nucleus pulposus extrusion had good outcomes. Acute non-compressive nucleus pulposus extrusion should be considered as a differential diagnosis for cats presenting with peracute onset of spinal cord dysfunction, particularly if there is a clinical history

HERNIAS DISCALES TRAUMATICA DE DISCO NO DEGENERADO

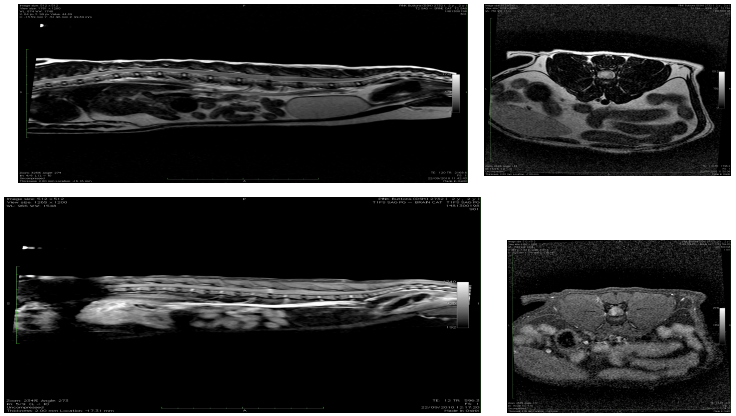

TUMORES ESPINALES GATOS

Tumors affecting the spinal cord of cats: 85 cases (1980–2005)

Katia Marioni-Henry, DVM, PhD, DACVIM; Thomas J. Van Winkle, VMD, DACVP; Sionagh H. Smith, BVMS, PhD, DACVP; Charles H. Vite, DVM, PhD, DACVIM

Objective—To determine the prevalence of lymphosarcoma and other tumors affecting the spinal cord of cats and to relate specific types of tumors with signalment, history, and clinical findings.

Design—Retrospective case series.

Animals—85 cats with tumors affecting the spinal cord.

Procedures—Medical records of cats with histologically confirmed primary or metastatic tumors of the spinal cord or tumors causing spinal cord disease by local extension from adjacent tissues examined between 1980 and 2005 were reviewed. Data on signalment; clinical history; results of neurologic examination, diagnostic imaging, and clinical pathologic evaluation; and location of tumor within the spinal cord were obtained from medical records and analyzed by use of logistic regression models.

Results—Lymphosarcoma was the most common tumor and affected the spinal cord in 33 (38.8%) cats, followed by osteosarcoma in 14 (16.5%) cats. Cats with lymphosarcoma were typically younger at initial examination, had a shorter duration of clinical signs, and had lesions in more regions of the CNS than did cats with other types of tumors. In 22 of 26 (84.6%) cats with lymphosarcoma, the tumor was also found in extraneural sites.

Conclusions and Clinical Relevance—Data for spinal cord tumors in this population of cats were analyzed by logistic regression analysis, which effectively distinguished cats with lymphosarcoma from cats with other types of tumors. Additional clinical information reported here will help to increase the index of suspicion or definitive antemortem diagnosis of spinal cord tumors of cats. (*J Am Vet Med Assoc* 2008;232:237–243)

TUMORES ESPINALES GATOS

bral or spinal cord tumors treated with surgical cytoreduction, meningioma was the

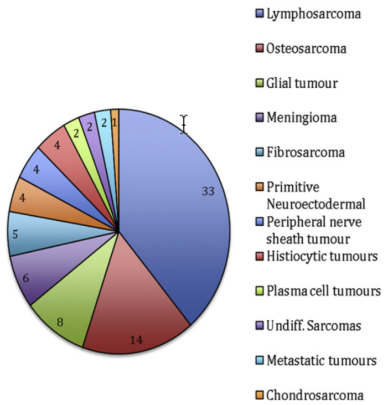

Fig. 2. Prevalence of tumors in a population of 85 cats with histologically confirmed of spinal cord tumors of cats. (*J Am Vet Med Assoc* 2008;232:237–243)

TUMORES ESPINALES

Tumores espinales felinos

- Media de edad 8.1 años (0.5-16 años)

- Linfoma 38,8%

Jóvenes, < duracion signos clínicos, multifocal

Felv > 56%/ FIV 14%

84.6% extraneural (médula ósea, renal)

43% invasion cerebral

- Osteosarcomas vertebrales 16,5%

- Gliales 9,4% (cervical)

- Meningiomas 7 %

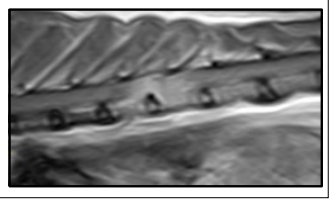

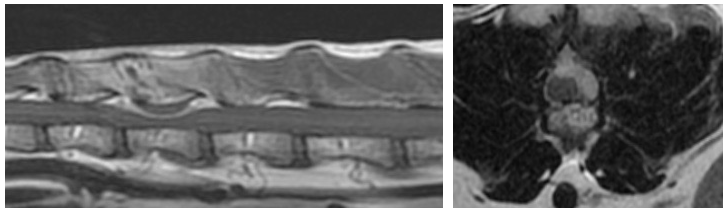

LINFOMA CERVICAL

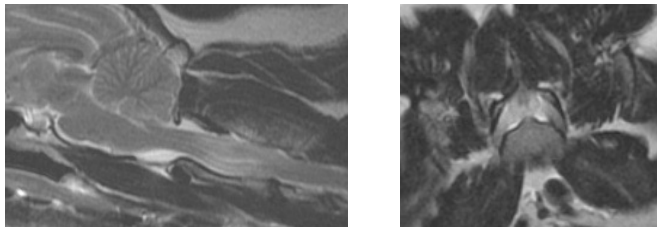

LINFOMA TORACICO

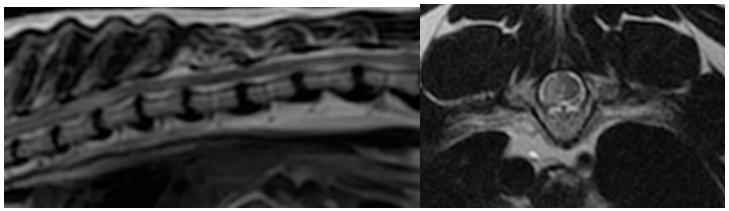

TUMORES ESPINALES

Tratamiento

Linfomas

Quimioterapia, radioterapia, cirugia

Pronóstico reservado

completa remisión signos clínicos (50%) N=6
Media de remisión 14 semanas

Spodnick et al, JAVMA 1992 (N=21)

No linfoides

Citoreduccion quirúrgica (Meningiomas)

Pronóstico asociado al fenotipo tumoral

Malignos (osteosarcomas) Media 110 días

Benignos (meningiomas) Media 518 días

Rossmeisl et al, Vet Comp Oncology 2006

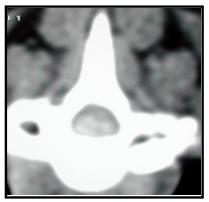

MENINGIOMAS

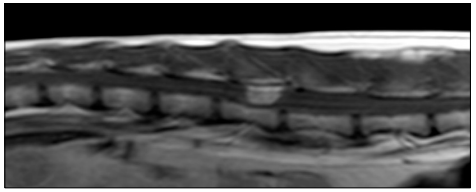

TRAUMATISMOS ESPINALES

-*Fracturas o luxaciones vertebrales*
(concusion, compresion, contusion, laceracion)

Hernia discal aguda Hansen I (concusión, compresión, contusión)

D

Enfermedades neoplásicas (fracturas patológicas, hemorragia)

Enfermedades vasculares (EFC) (infarto)

- Caidas, disparos, accidentes via pública, mordeduras, etc

TRAUMATISMOS ESPINALES

Manejo del paciente con traumatismo espinal - Medidas iniciales

Inmovilización del paciente: Cuidado al moverlo fractura/luxación??

ABC: Airway, Breathing and Circulation

Analíticas sanguíneas completas/presión arterial
Pruebas coagulación si necesario
Examen físico general completo *(TRC, mucosas, auscultación...)*

- Examen neurológico

-Localización de la lesión (ojo shock espinal)

-Severidad de la lesión/ pronóstico

PRESENCIA DE SENSIBILIDAD DOLOROSA NO REFLEJO

TRAUMATISMOS ESPINALES

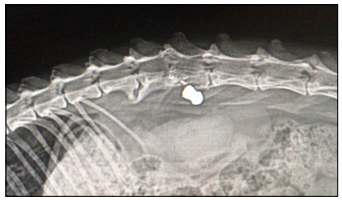

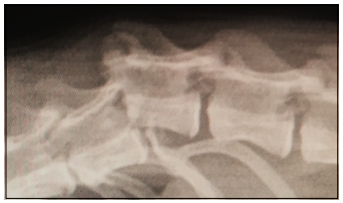

TRAUMATISMOS ESPINALES

DIAGNOSTICO Y PRONOSTICO

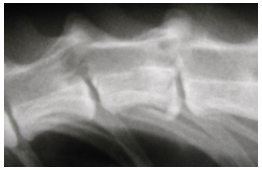

Analíticas completas/urianalisis

Radiografías torácicas/ ecografía abdominal

Sospecha de inestabilidad (fractura/luxación)

- Radiografía lateral de la columna

No radiografías ventro-dorsales si sospecha o confirmación de
fractura/luxación por Rx lateral

Ojo al sedarlos (musculatura relajada mas facil agravar la luxacion o fractura

TRAUMATISMOS ESPINALES

Mielografia

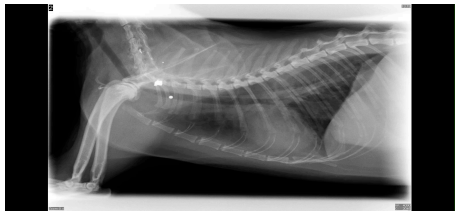

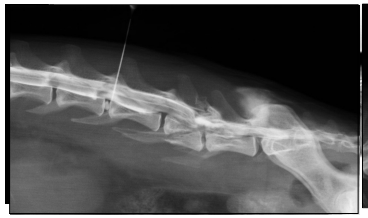

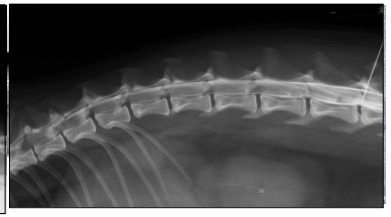

TRAUMATISMOS ESPINALES

Mielografia

Dural tear and myelomalacia caused by an airgun pellet in a cat

Cristian de la Fuente, Sergio Ródenas, Martí Pumarola, Sònia Añor

Abstract — An 8-year-old cat was presented with severe neurological deficits secondary to a traumatic cervical spinal cord injury caused by an airgun pellet. This report describes, for the first time, the myelographic findings of a dural rupture in a cat and also describes a bilateral Horner's syndrome in a cat.

Résumé — Déchirure durale et myélomalacie causées par le plomb d'un pistolet pneumatique chez un chat. Un chat âgé de 8 ans a été présenté avec des déficits neurologiques graves secondaires à une blessure traumatique de la moelle épinière cervicale causée par le plomb d'un pistolet pneumatique. Ce rapport décrit, pour la première fois, les résultats myélographiques d'une rupture durale chez un chat et aussi un syndrome de Horner chez un chat.

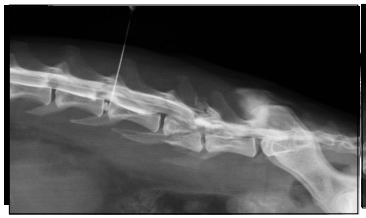

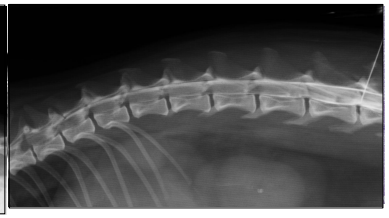

TRAUMATISMOS ESPINALES

TAC

MAYOR SENSIBILIDAD PARA TEJIDO OSEO QUE RADIOGRAFIA Y RMN
GRAN UTILIDAD PARA PLANEAR CIRUGIA (IMPLANTES)
RECONSTRUCCION EN 3D

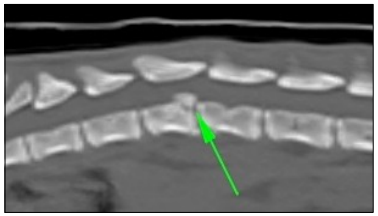

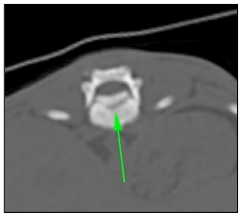



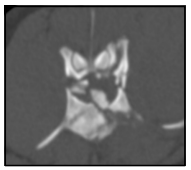

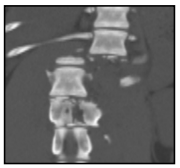

TRAUMATISMOS ESPINALES

TRATAMIENTO

- CONSERVADOR

Indicado si pocos déficits neurológicos
Motivos económicos
Reposo absoluto y collarin 4-6 semanas
Contusiones medulares sin fractura

- CIRUGIA

Generalmente es de indicación quirúrgica
Cemento, placas, etc
Riesgo peri y post-quirurgico
Implantes en el canal, problemas respiratorios
MAYORIA DE CASOS CIRUGIA TECNICA DE ELECCION



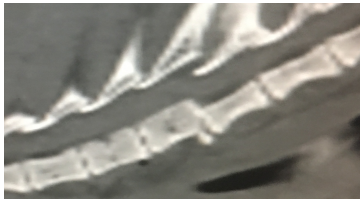

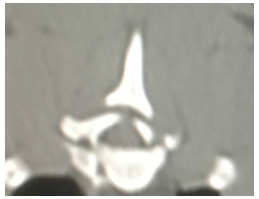

ANOMALIA CONGENITA

NO COMUNES

MALFORMACION DE CHIARI
SIRINGOMIELIA
AGENESIA SACRO-CAUDAL, MIELO/MENINGOCELES
QUISTES GANGLIONARES INTRADURALES, ARACNOIDEOS, ETC

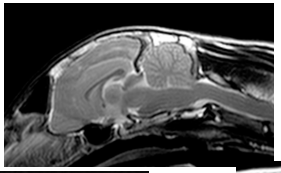

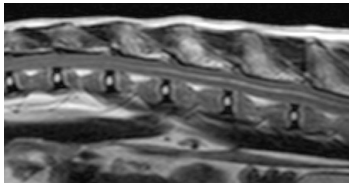

ANOMALIA CONGENITA

NO COMUNES

- MALFORMACION DE CHIARI
- SIRINGOMIELIA
- AGENESIA SACRO-CAUDAL, MIELO/MENINGOCELES
- QUISTES GANGLIONARES INTRADURALES, ARACNOIDEOS, ETC

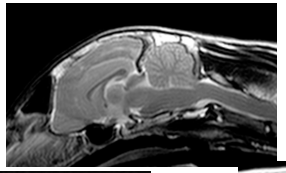

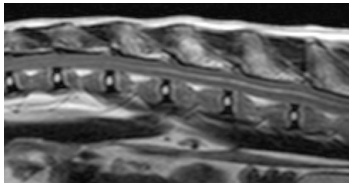

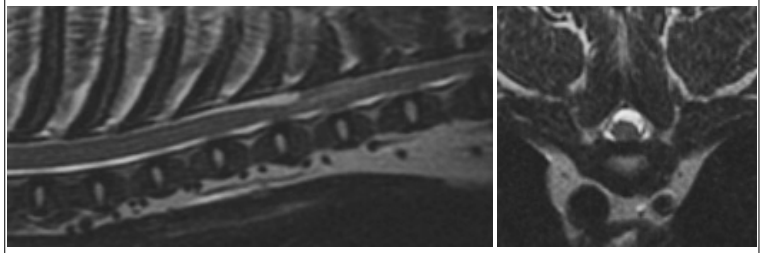

DIVERTICULO ARACNOIDEO